

Detection of asymptomatic lesions in jaws from patient visiting King Saud University (KSU) College of Dentistry: A retrospective study

Naveed Ahmad Khawaja^{1,2*}, Mohammed Al Ali³, Ahmed Bu Mozah³, Hussain Al Marhoon³

¹Former Faculty, Maxillofacial Surgery and Diagnostic Sciences, College of Dentistry, King Saud University, Riyadh-KSA

²HOD/Associate Professor, Oral Pathology, CIMS Dental College, Multan-Pakistan

³Former Intern, College of Dentistry, King Saud University, Riyadh-KSA

Abstract

The aim of this study was to evaluate the detection of asymptomatic lesions of jaws in retrospective two-year panoramic radiographs from patients' record visiting for treatment in the College of Dentistry, King Saud University, and accidentally noticed while patients visited for other reasons. Ninety-two (92) cases were selected for the study to detect asymptomatic lesions among 907 patients varying in age of 18 to 72 years (mean 38 years) and who visited the Dentistry College. The information was collected on a designed proforma by two examiners and calculated average. Seventy-six (76) were male and sixteen (16) females, including 79 (85.9%) radiopaque, 11 (12%) radiolucent, and 2 (2.2%) with mixed lesions. These results showed no significant gender differences. The selected cases were divided into three age groups 18-30, 31-50, and 51-72 years to detect different lesions, but the groups did not differ significantly. In this study, location-wise frequency of lesions in the anterior region of jaws were 2 (28.6%) in maxilla and 5 (71.4%) in mandible, whereas in the posterior region 7 (9.7%) were in maxilla and 65 (90.3%) in mandible. However, the study concluded that most of asymptomatic radiopaque lesions were found in the posterior region of mandible and more incidence being in young age group.

SECTION

Human Biology (HB)

HANDLING EDITOR

Ashraf, M.A.B. (HB)

ARTICLE HISTORY

Received: 22 Sep, 2023

Accepted: 01 Jan, 2024

Published: 02 Jan, 2024

KEYWORDS

Asymptomatic;
Intraosseous pathology;
Panoramic radiographs;
Radiopaque-lucent
images

Introduction

Asymptomatic lesion is defined as any lesion without complaint that has been detected accidentally through routine panoramic radiographs while patients visit for any other problem (Brody et al., 2019). Most of the asymptomatic lesions are residual or reactive lesions that appear as non-specific response of tissues. Some are found radiopaque but others are radiolucent and mixed in jawbone (Avril et al., 2014).

Panoramic radiograph screening is a basic initial diagnostic tool to determine intraosseous pathology. Panoramic radiograph can be used as a tool to diagnose degree of bony changes (Richardson, 1997; Tang et al., 2017). Moreover, it is a simple extra-oral investigation to perform, convenient for the patients and easily available. A similar study by Araki et al. (2011) conducted on panoramic radiography and cone-beam computed tomography to analyze asymptomatic lesions from 1998-2002 reported a large majority of radiopaque lesions in premolar and molar sites of the mandible; 60% of lesions were periapical, 24% were in the body, and 16% in the edentulous region. In another study while evaluating

***CONTACT** Naveed Ahmad Khawaja, ✉ nakhawaja@yahoo.com, 📠 Former Faculty, Maxillofacial Surgery and Diagnostic Sciences, College of Dentistry, King Saud University, Riyadh-KSA/HOD/Associate Professor, Oral Pathology, CIMS Dental College, Multan-Pakistan

TO CITE THIS ARTICLE: Khawaja, N.A., Ali, M.A., Mozah, A.B., Marhoon, H.A. (2024). Detection of asymptomatic lesions in jaws from patient visiting KSU College of Dentistry: A retrospective study. *International Journal of Applied and Experimental Biology* 3(1): 25-30.

asymptomatic intraosseus radiographic findings, Javadian et al. (2014) reported mostly radiolucent 30 (96.8%) being higher in frequency and radiopaque 7 (38.8%) in equal gender distribution. In the same study, cysts occurred more in anterior maxilla, i.e. 9 (29%) and posterior region of mandible, i.e. 14 (45.2%) as compared to tumors and tumor-like lesions. The findings showed that most of the lesions were unilocular well-corticated pertaining to cysts and tumor-like lesions.

The principal objective of this study was to detect asymptomatic lesions in panoramic radiographs (OPG) in retrospective two years from the patients' records who visited KSU College of Dentistry, Riyadh.

Material and Methods

A randomly 907 patients' hospital records were examined for panoramic radiographs in retrospective two years. Ninety-two (92) file records were selected for the study to identify detectable asymptomatic lesions from age 18-72 who were treated in the Dental College of King Saud University for other problems.

Two examiners reviewed screening the panoramic radiographs (OPG) to confirm findings for asymptomatic lesions using patient file records of two years having panoramic radiographs for detectable lesions using x-ray illuminator and magnifying lens. We included most of detectable bony lesions/detectable abnormalities seen within jaws, whereas the remaining roots, teeth related lesions and impacted teeth were considered as excluding criteria for this study. All data were collected in a designated proforma to evaluate panoramic radiographs.

Screening included mainly asymptomatic lesions noticed during dental treatment, whether treated or followed/or not. We divided jaw into two portions to detect asymptomatic pathological images in the bone:

- Anterior body of mandible/maxilla (anterior teeth bearing bone)
- Posterior body of mandible/maxilla (posterior teeth bearing bone up to angle in mandible and maxillary tuberosity in maxilla)

The screening criteria we followed for asymptomatic lesions were:

1. Radiolucent (black shadow) showing an area with a bony density that was less than the surrounding bone and was well circumscribed.
2. Radiopaque (white shadow) showing an area with a bony density that was greater than the surrounding bone and was well circumscribed.
3. Mixed (white and black) which was an area that demonstrated a mixture of the above two shadows.

Most of the radiographs were exposed through an X-Ray machine "Siemens" Orthopantomograph. The machine delivered 1 x 10 Gy/sec at 8 mA for 22 seconds, resulting in a total patient dose of 2.2 x 10 Gy per radiograph.

Demographic and radiographic reports were retrieved from the files of the patients. In this study, patient's age was divided into three age groups: 18-30, 31-50, and 51-72 years. The area and location of the lesions were determined by examining on panoramic radiograph films using formatted form. Each radiographic film was reviewed by two examiners using identical viewing conditions to reduce error. Acceptable quality radiographs were included in this study as selection criteria. Moreover, we also retrieved two cases among our samples, and diagnosis confirmed by histopathological which were treated and followed-up.

Statistical analysis of data

Statistical analysis of data was performed using the current version of the SPSS software. Comparison of data sets was carried out by chi-squared test. Mean values differed significantly at $P < 0.05$.

Results

Among 907 patient files, randomly 92 (10.1%) panoramic radiographs were selected for this study to determine asymptomatic lesions. Seventy-six (76) were male and 16 female. Among 76 males, radiopaque lesions were detected 66 (86.8%), radiolucent 9 (11.68%) and mixed 1 (1.3%). While in 16 females, 13 (81.3%) were radiopaque, 2 (12.5%) radiolucent and 1 (6.3%) with mixed lesions (**Table 1**).

Table 1. Relationship of gender to different radiologic lesions

			Lesions			Total
			RO	RL	Mixed	
Gender	Male	<i>n</i>	66	9	1	76
		%	86.8	11.8	1.3	100
	Female	<i>n</i>	13	2	1	16
		%	81.3	12.5	6.3	100
Total			<i>n</i>	79	11	93
			%	85.9	12.0	2.2

n = number of patients; RO = radiopaque; RL = radiolucent

Incidence of lesions in the first age group was: 34 (91.9%) radiopaque, 2 (5.4%) radiolucent and 1 (2.7%) mixed, whereas in the second group, radiopaques were found as 23 (74.2%), radiolucents 8 (25.8%) and no one with mixed lesions. In the third group, radiopaques were found as 20 (90.9%), radiolucents 1 (4.5%) and 1 (4.5%) with mixed lesions. However, this study concluded that radiopaque lesions were more common in the first age group in comparison to the other age groups (Table 2), that is mostly non-specific response of tissue to periapical infections/or residual infections and periodontal infections (Table 2).

Table 2. Incidence of different lesions in three age groups

		Lesions				Total
		RO	RL	Mixed		
Age groups (Years)	18-30	<i>n</i>	34	2	1	37
		%	91.9	5.4	2.7	100
	31-50	<i>n</i>	23	8	0	31
		%	74.2	25.8	0	100
	51-72	<i>n</i>	20	1	1	22
		%	90.9	4.5	4.5	100
Total	<i>n</i>	77	11	2	90	
	%	85.6	12.2	2.2	100	

n = number of patients; RO = radiopaque; RL = radiolucent

This study shows distribution of radiopaque lesions in different regions in both jaws. Incidence of lesions was mostly in mandible than that in maxilla. In mandible, most of the radiopaque lesions were found in the posterior area (65; 92.9%) comparing to the anterior area with 5 patients (7.1%) in the mandible, whereas 7 (77.8%) were found in the posterior maxilla and 2 (22.2%) in the anterior maxilla (Table 3). These findings show that bone of the posterior region of mandible is thicker and has a good blood supply which is more vulnerable to produce changes in response to residual infections and functional elements (Table 3).

Overall, the results of this study show that most of radiopaque lesions (65, 92.9%) were found in the posterior region of mandible (Figure 1).

Two cases were reported from the patients treated/followed for excisional biopsy in Oral & Maxillofacial Surgery Department and diagnosed by histopathological reports as hemorrhagic bone cyst and condensing osteitis/compact osteoma.

Table 3. Relationship of incidence of radiopaque lesions of jaw to position

			Position		Total
			Anterior	Posterior	
Jaw	Maxilla	<i>n</i>	2	7	9
		%	22.7	77.8	100
	Mandible	<i>n</i>	5	65	70
		%	7.1	92.9	100
Total			<i>n</i>	7	79
			%	8.9	100

n = number of patients

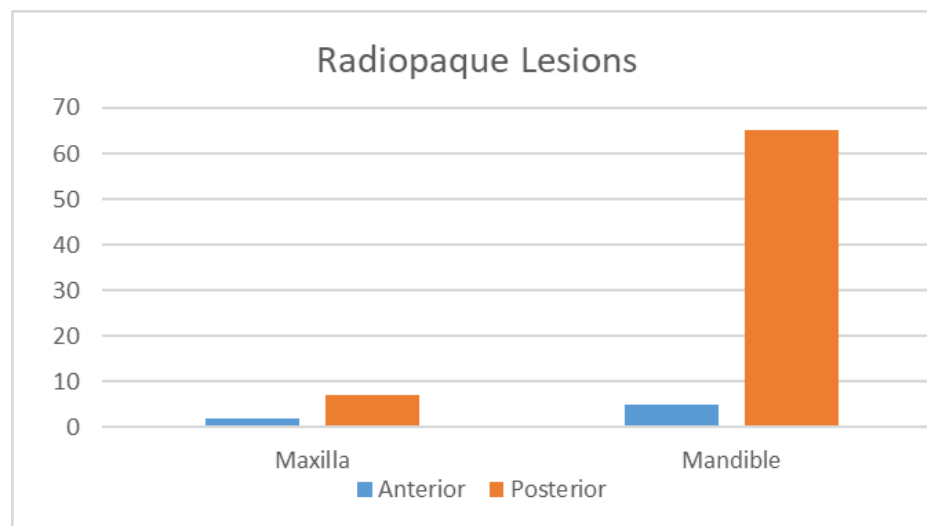


Figure 1. Distribution of radiopaque lesions in jaw anterior and posterior areas

Discussion

This study investigated the retrospective two-year panoramic findings from 92 patient files to find asymptomatic lesions accidentally when patients visited to clinic with another problem. The study concluded that most of the radiopaque lesions were found in the posterior region of mandible, and mostly in younger age group. It could be non-specific reaction of tissue to residual infection, both either bone production (dense) or destruction (thin) (Panteli and Giannoudis, 2017). The nature of reaction is usually sclerotic apparently brought by good patient resistance coupled with a few degrees of virulence of offending bacteria which are more commonly seen in the younger patients (Farquharson et al., 2012). Nevertheless, the offending tooth is extracted whether with periapical or periodontal infection, and bone changes may remain in the jaws indefinitely as asymptomatic depending on the resistance of patients (Neville et al., 2015). In an analogous study, Araki et al. (2011) analyzed the frequency of significant pathology findings in retrospective four-year record of panoramic radiographs and CBCT reported soft tissue calcifications and radiopaque-radiolucent lesions in the posterior mandible other than impacted, root fragments, foreign bodies, and mucous retention cysts in 256 (34%) out of 743 asymptomatic edentulous patients. However, this study reported the most of radiopaque lesions 6.5 (92.9%) in the posterior region of mandible, and in younger age group (91.9%). Similarly, a case report by Clark et al. (2005a,b) presented a case to develop 3 x 4 cm asymptomatic unilocular radiolucency on the left retromolar area with a subtle erosion of distal root of mandibular second molar following the removal of third molars over 10 years before in a 40-year old African-American male while he underwent an initial dental screening.

Despite development of various imaging modalities, panoramic radiography provides the early detection of lesions in jaw bones that in turn enables the dentist to screen out further and referral to a specialist for diagnosis as well as further treatment strategy. However, panoramic is an excellent radiograph and moreover it can be easily used as a primary tool to analyze any lesions in the jaw bones. It provides a significant gross image of the maxillofacial skeleton and dentition (Neyaz et al., 2008). One similar old study by Edgerton and Clark (1991) also concluded with the same results on examination of panoramic radiographs in edentulous patients for abnormalities and mostly found radiopaque image in the remaining roots intra-bony, but frequency of radiolucent lesions was the similar as in the present study. This study also reported radiographic lesion images in both jaws in different age groups and site-wise in the anterior and posterior regions of jaws. However, this study aimed to screen only asymptomatic lesions not associated with teeth, that could be residual lesions either radiopaque or radiolucent located in the anterior and posterior portions of jaws in different age groups.

While evaluating asymptomatic interosseous on panoramic images, Javadian et al. (2014) encountered mostly tumor-like lesions with a higher frequency in females in the posterior mandibular region and noticed 8% residual cyst and 11 (92%) idiopathic bone cavity as radiolucent, and well-defined, diffuse border radiopaque lesions diagnosed as osteosclerosis. These are mostly unilocular radiolucency pertaining to cysts and benign tumors. Subsequently, Kose et al. (2015) conducted a similar study in 743 asymptomatic edentulous patients, and 331 digital panoramic radiographs were selected out of 256 (34%) patients and detected asymptomatic pathology to be required surgical treatment before prosthetic treatment. This study also concluded more radiopaque lesions in middle-age group (31-50 years) as well and even in the posterior maxilla 7 (77.8%).

Despite its known shortcomings, and like every other diagnostic tool, panoramic radiography can contribute to the early detection of maxillary/mandibular jaw lesions that in turn enables the dentist to devise an appropriate treatment plan. Moreover, the panoramic radiograph is a significant and easily available image to study gross interosseous abnormalities and pathologic conditions of jaws in the images of radiopaque, radiolucent and mixed lesions, but it does not provide fine radiographic detail.

In summary, this research emphasizes higher percentage of radiopaque lesions in the posterior region of mandible and more found in younger age group. It was also emphasized from different studies that panoramic radiograph is necessary to explore asymptomatic pathology before going for prosthodontic and implant treatment. The study can be extended in future to evaluate tooth related-pathology and other interosseous abnormalities followed by final histopathological diagnosis.

Author(s), Editor(s) and Publisher's declarations

Acknowledgement

The authors gratefully acknowledge the lab field staff for their technical help.

Conflict of interest

The authors declare no conflict of interest.

Source of funding

Declared none.

Contribution of authors

Conceptualized and designed the study: NAK. Wrote-up the first draft of the manuscript: NAK, MAA, ABM, HAM. Reviewed and edited the manuscript, all authors. All authors have read, reviewed and agreed to publish the current version of the manuscript in IJAaEB.

Ethical approval

This work was approved by Institutional Ethical Review Board/Committee (IERB/C) of the King Saud University, Riyadh-KSA

Handling of bio-hazardous materials

The authors certify that all experimental materials were handled with care during collection and experimental procedures. After completion of the experiment, all materials were properly discarded to minimize any types of bio-contamination(s).

Availability of primary data and materials

As per editorial policy, experimental materials, primary data, or software codes are not submitted to the publisher. These are available with the corresponding author and/or with other author(s) as declared by the corresponding author of this manuscript.

Authors' consent

All authors contributed in designing and writing the entire article. All contributors have critically read this manuscript and agreed for publishing in IJAaEB.

Disclaimer/Editors'/publisher's declaration

All claims/results/prototypes included in this manuscript are exclusively those of the authors and do not inevitably express those of their affiliated organizations/enterprises, or those of the publisher/journal management, and the editors/reviewers. Any product mentioned in this manuscript, or claim rendered by its manufacturer, is not certified by the publisher/Journal management. The journal management disown responsibility for any injury to organisms including humans, animals and plants or property resulting from any ideas/opinions, protocols/methods, guidelines or products included in the publication.

Declaration of Generative AI and AI-assisted technologies in the writing process

It is declared that we the authors did not use any AI tools or AI-assisted services in the preparation, analysis, or creation of this manuscript submitted for publication in the International Journal of Applied and Experimental Biology (IJAaEB).

References

- Alatter, M.M., Baushman, R.A., Collett, W.K. (1980). A survey of panoramic radiographs for evaluation of normal and pathological changes. *Oral Surgery, Oral Medicine, Oral Pathology* 50:472-480. doi: [10.1016/s0030-4220\(80\)80017-x](https://doi.org/10.1016/s0030-4220(80)80017-x)
- Araki, M., Matsumoto, N., Matsumoto, K., Ohnishi, M., Honda, K., Komiyama, K. (2011). Asymptomatic radiopaque lesions in the jaws: a radiographic study using cone-beam computed tomography. *Journal of Oral Science* 53:439-444. doi: [10.2334/josnurd.53.439](https://doi.org/10.2334/josnurd.53.439).
- Ardekani, F.E., Navab Azam, A.R. (2007). Radiological findings in panoramic radiographs of Iranian edentulous patients. *Oral Radiology* 23:1-5.
- Avril, L., Lombardi, T., Ailianou, A. (2014). Radiolucent lesions of the mandible: a pattern-based approach to diagnosis. *Insights into Imaging* 5:85-101. doi: [10.1007/s13244-013-0298-9](https://doi.org/10.1007/s13244-013-0298-9)
- Boonyapakorn, T., Supanchart, C., Reichart, P.A. (2006). Radiopaque lesion with periapical radiolucency of the mandible. *Oral Surgery, Oral Medicine, Oral Pathology, Oral Radiology and Endodontics* 102:713-718. doi: [10.1016/j.tripleo.2006.02.027](https://doi.org/10.1016/j.tripleo.2006.02.027)
- Brody, A., Zalatnai, A., Csomo, K., Belik, A., Dobo-Nagy, C. (2019). Difficulties in the diagnosis of periapical translucencies and in the classification of cemento-osseous dysplasia. *BMC Oral Health* 19:139. <https://doi.org/10.1186/s12903-019-0843-0>
- Clark, C.K., Thompson, S.H., Brown, S.A., Fielding, C., Baur, D.A., Helman, J.I. (2005). Asymptomatic radiolucent lesion of posterior mandible. Clinicopathologic Conference. *Journal of Oral and Maxillofacial Surgery* 63(3):377-381.
- Edgerton, M., Clark, P. (1991). Location of abnormalities in panoramic radiographs of edentulous patients. *Oral Surgery, Oral Medicine, Oral Pathology* 71:106-109. doi: [10.1016/0030-4220\(91\)90535-k](https://doi.org/10.1016/0030-4220(91)90535-k)
- Farquharson, D., Butcher, J.P., Culshaw, S. (2012). Periodontitis, porphyromonas, and the pathogenesis of rheumatoid arthritis. *Mucosal Immunology* 5(2):112-120.
- Javadian Langaroodi, A., Lari, S.S., Shokri, A., Hoseini Zarch, S.H., Jamshidi, S. (2014). Intraosseous benign lesions of the jaws: A radiographic study. *Iranian Journal of Radiology* 11:e7683. doi:10.5812/iranjradiol.7683.
- Kose, T.E., Demirtas, N., Ozcan, I. (2015). Evaluation of dental panoramic radiographic findings in edentulous jaws: A retrospective study of 743 patients "Radiographic features in edentulous jaws". *The Journal of Advanced Prosthodontics* 7:380-385. doi: [10.4047/jap.2015.7.5.380](https://doi.org/10.4047/jap.2015.7.5.380). Epub.
- Neville, B.W., Damm, D.D., Allen, C.M., Bouquot, J.E. (2015). "Oral and Maxillofacial Pathology," 4th edition. Elsevier Health Sciences.
- Neyaz, Z., Gadodia, A., Gamanagatti, S., Mukhopadhyay, S. (2008). Radiological approach to jaw lesions. *Singapore Medical Journal* 49(2):165-176.
- Panteli, M., Giannoudis, P.V. (2017). Chronic osteomyelitis: what the surgeon needs to know. *EFORT Open Reviews* 1(5):128–135. <https://doi.org/10.1302/2058-5241.1.000017>
- Richardson, P.S. (1997). Selective periapical radiology compared to panoramic screening. *Primary Dental Care* 4:95-99. doi: [10.1016/j.ident.2012.04.018](https://doi.org/10.1016/j.ident.2012.04.018)
- Tang, Z., Liu, X., Chen, K. (2017). Comparison of digital panoramic radiography versus cone beam computerized tomography for measuring alveolar bone. *Head & Face Medicine* 13(1):2. doi: [10.1186/s13005-017-0135-3](https://doi.org/10.1186/s13005-017-0135-3)